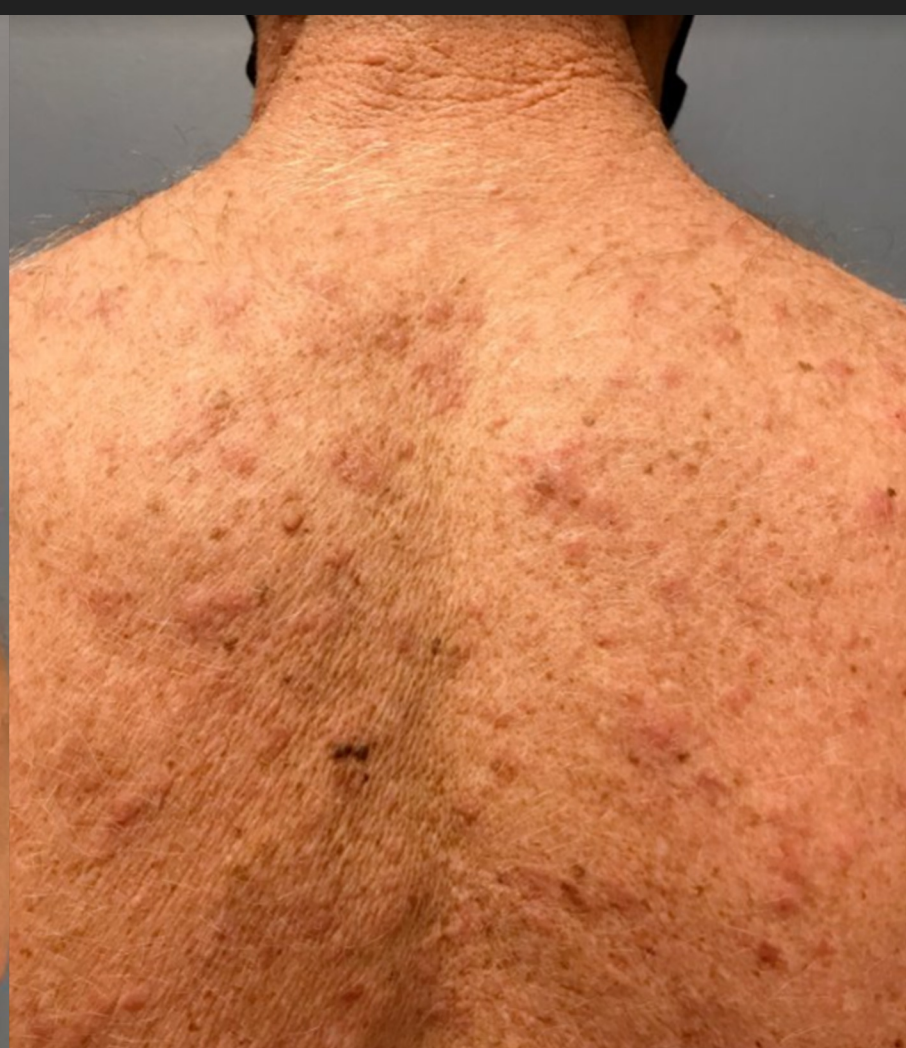
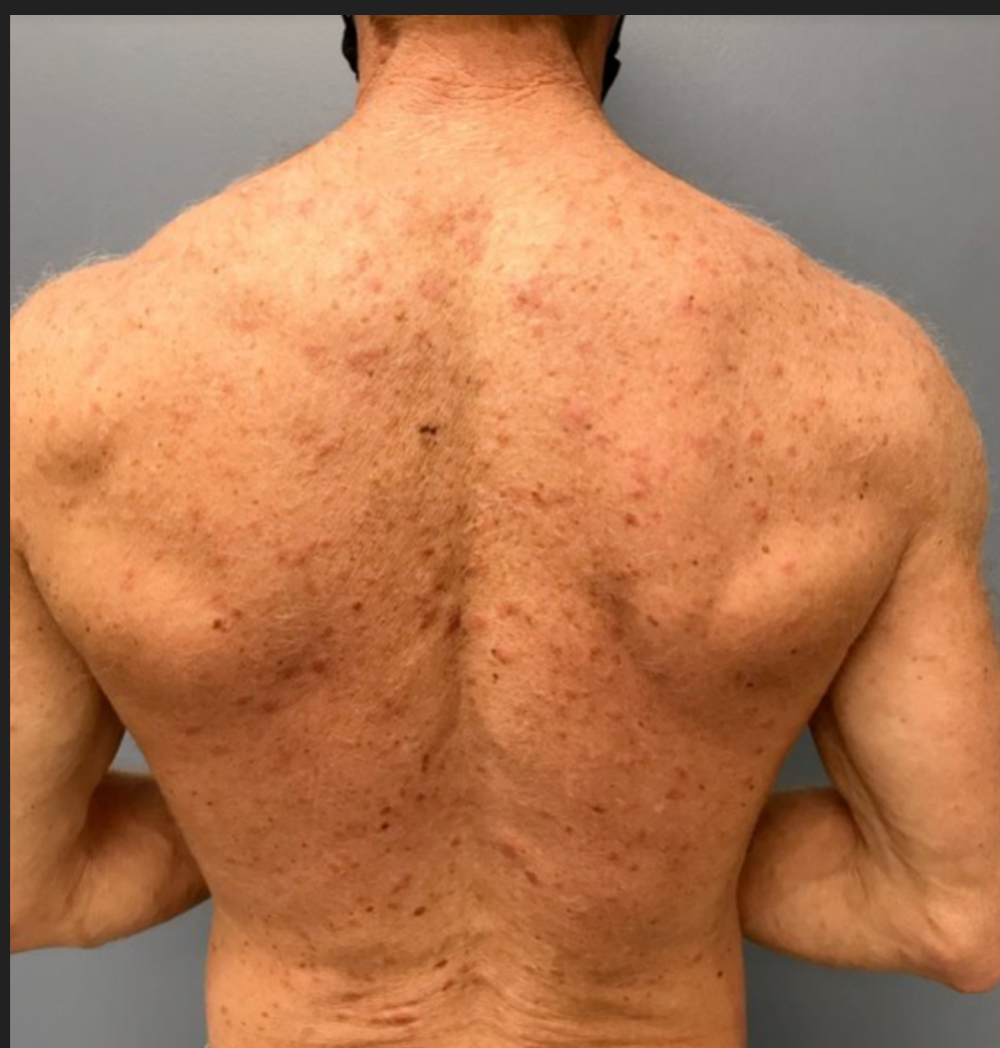
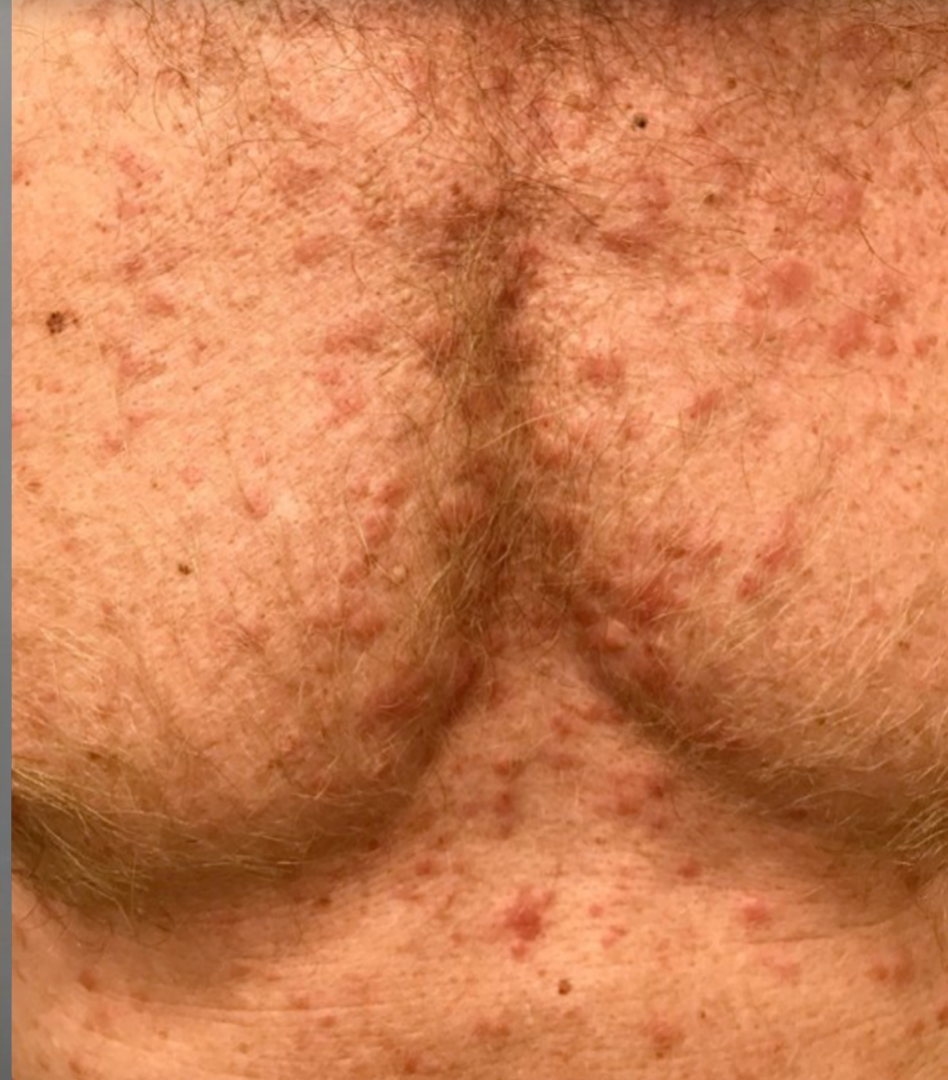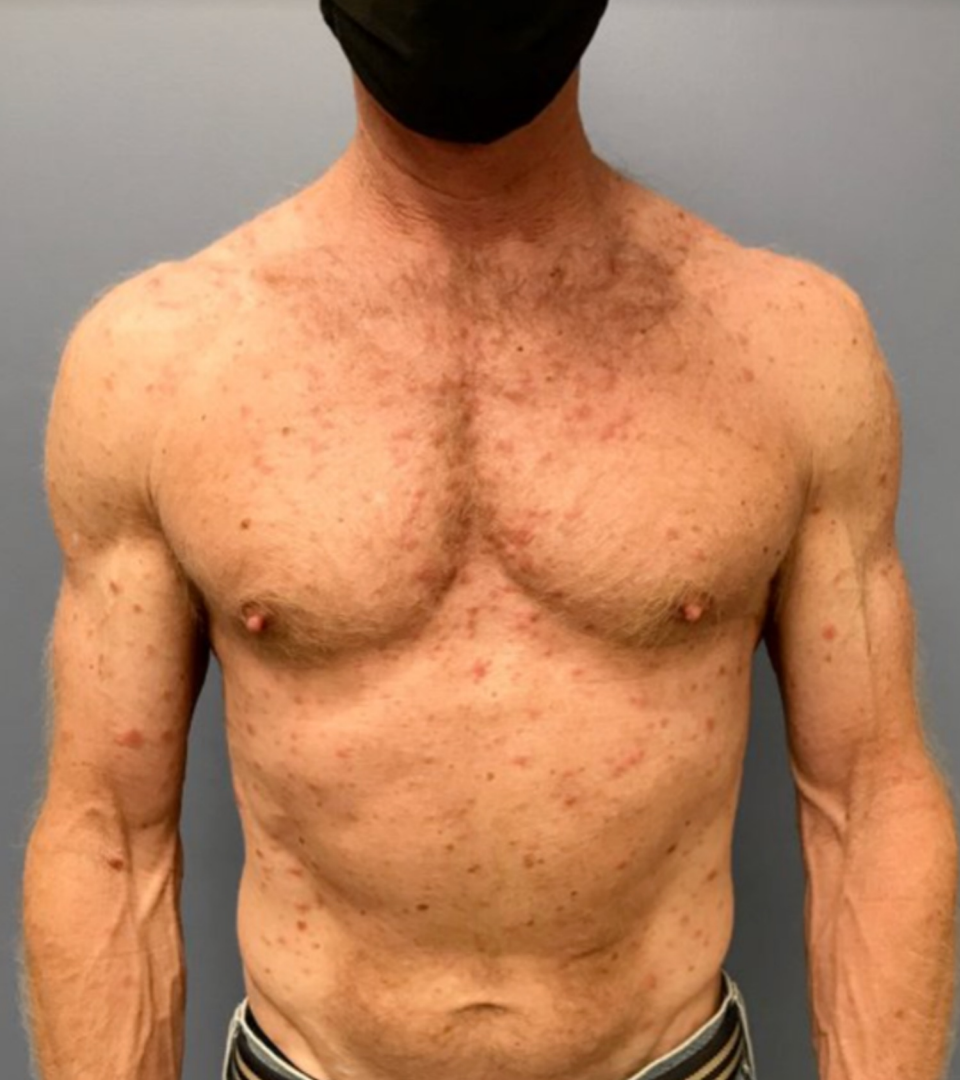Missouri Derm Case of the Month

Presented by: Lily Chen, Christine Yokoyama (PGY 3/PGY 4)
Washington University in St. Louis

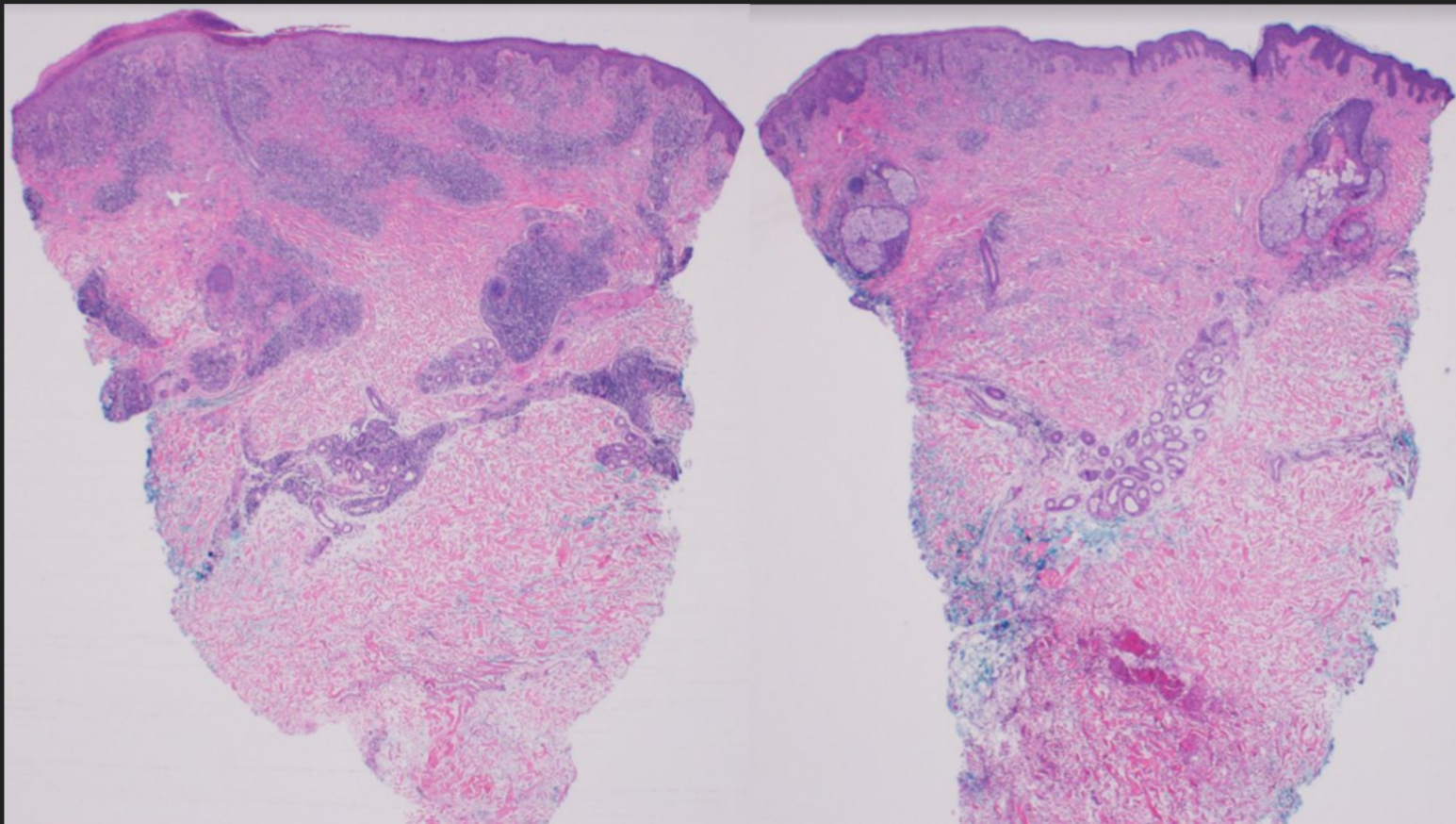
Patient Presentation

- A 52-year-old healthy man presented with three weeks of a diffuse, asymptomatic rash on the upper torso and arms associated with night sweats. On physical exam there were pink, edematous papulonodules over most of the body, including the face and scalp, but sparing the palms and soles.

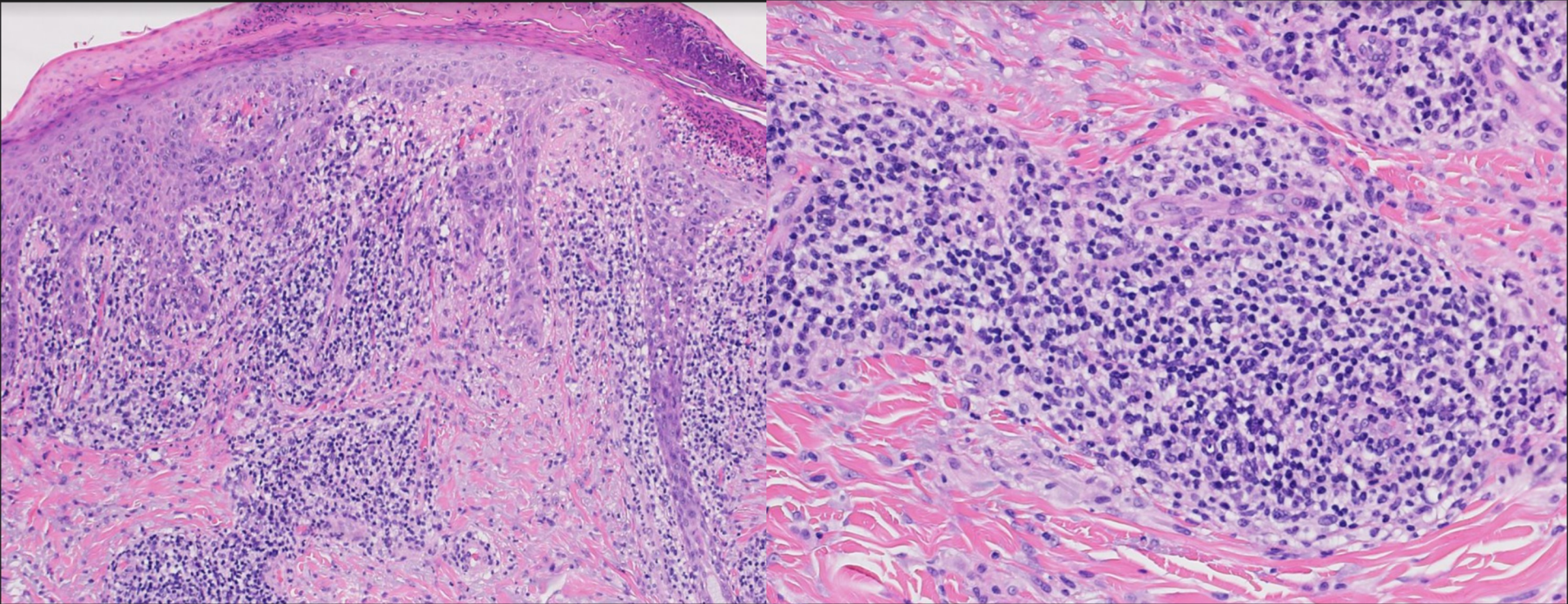




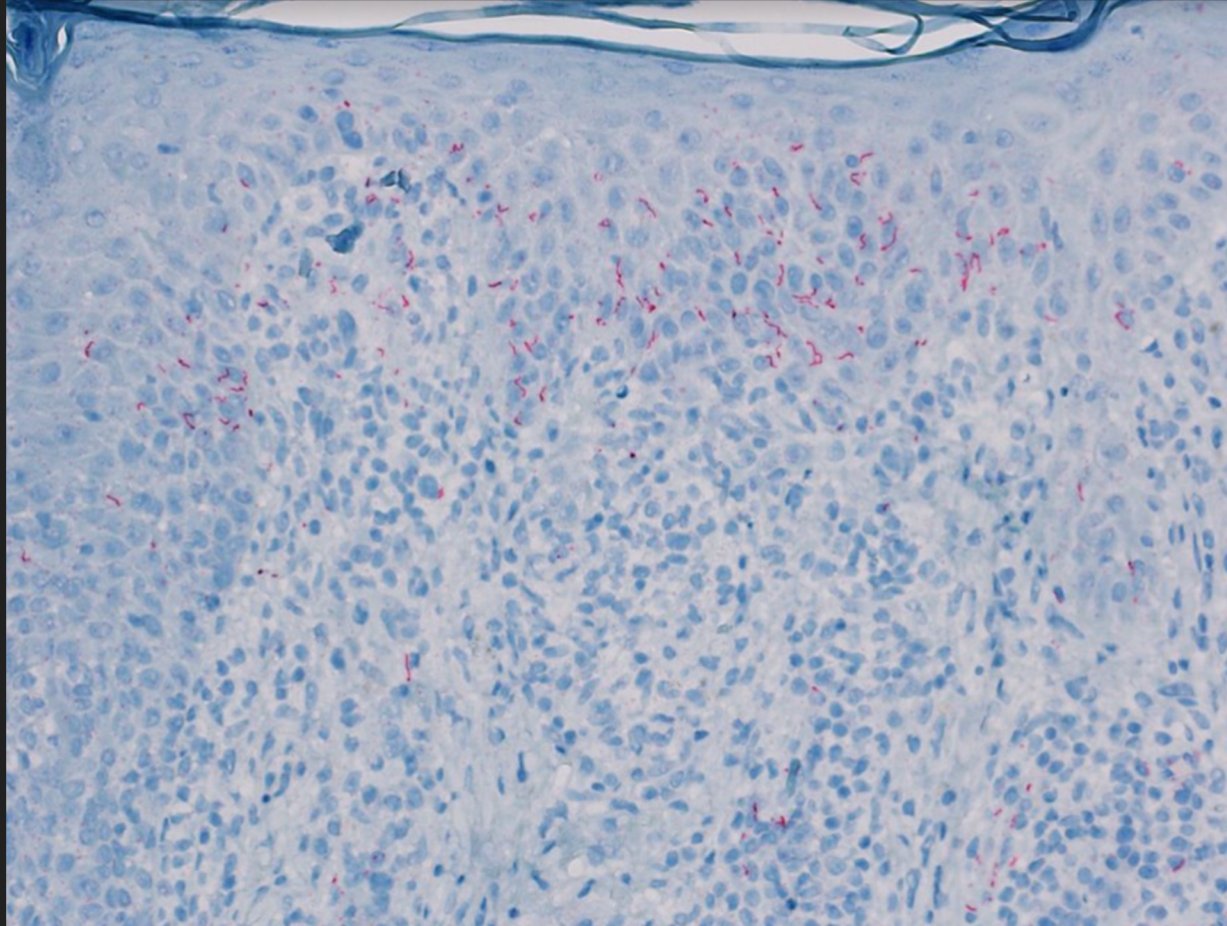
Histopathologic exam showed irregular epidermal hyperplasia, interface dermatitis and an interstitial granulomatous infiltrate within a robust, nodular lymphoplasmacytic background. Due to the presence of a mixed pattern dermatitis and plasma cells additional stains were obtained



Histopathologic exam showed irregular epidermal hyperplasia, interface dermatitis and an interstitial granulomatous infiltrate within a robust, nodular lymphoplasmacytic background. Due to the presence of a mixed pattern dermatitis and plasma cells additional stains were obtained



Unidentified stain...



Question 1: What is the diagnosis?

- A. Pityriasis rosea
- B. Guttate psoriasis
- C. Nodular secondary syphilis
- D. Drug eruption
- E. Scabies

Question 2: Based upon your diagnosis, what is the next best step?

- A. Screening for concomitant STD's
- B. Start Permethrin cream
- C. Begin a course of high dose topical steroids
- D. Reassurance that the lesions will resolve without treatment